



HEPATOPROTECTIVE ACTIVITY OF AQUEOUS ETHANOLIC EXTRACT OF AERIAL PARTS OF *GIVOTIA MOLUCCANA* L. ON CCl₄-INDUCED HEPATOTOXICITY IN RATS

Sateesh babu D*¹
Yanadaiah. JP¹
Lakshman kumar D¹
Siva Sankar Prasad K²
Siva Sankar S³

¹Department of Pharmacognosy,
PRRM College of Pharmacy,
Kadapa, Andhra Pradesh, India.

²Department of Pharmacology,
PRRM College of Pharmacy,
Kadapa, Andhra Pradesh, India.

³Research scholar, Department of
Material Science and Nano
technology, Yogi Vemana
University, Kadapa, Andhra
Pradesh, India.

ABSTRACT

Natural remedies from medicinal plants are considered to be effective and safe alternative treatment for liver injury. The present study was conducted to evaluate the hepatoprotective activity of aqueous ethanolic extract of aerial parts of *Givotia moluccana* L. in wistar rats. The study was conducted using the popular inducing agent carbon tetrachloride (0.1 ml/kg) in 1% olive oil and silymarin (20 mg/kg, p.o.) was used as reference standard in the respective model to treat for 21 days. The effect was estimated by measuring the enzymatic levels. The aqueous ethanolic extract of aerial parts of *Givotia moluccana* L. has shown very significant hepatoprotection against CCl₄-induced hepatotoxicity in wistar rats. This was evidenced by marked reduction in marker enzymes in the serum. Hepatotoxicity might be defined as any chemical agent that can be produced injury to the liver. Liver is involved with almost all the biochemical pathways to growth, fight against disease, nutrients supply, energy provision and reproduction. The major functions of the liver are carbohydrate, protein and fat metabolism, detoxification, secretion of bile and storage of vitamin.

Keywords: *Givotia moluccana*, Hepatoprotective activity, Ethanolic extract, Carbon tetrachloride, Silymarin.

INTRODUCTION

Herbs play a major role in the management of various liver disorders along with other system associated diseases. Liver is a key organ regulating homeostasis within the body by various functions. Liver injury caused by toxic chemicals and certain drugs has been recognized as a toxicological problem. Hepatotoxicity is one of very common ailment resulting in to serious debilities ranging from severe metabolic disorders to even mortality¹. Plants derived natural products such as tannins, flavonoids, glycosides and carbohydrates have received considerable attention in recent years due to their diverse pharmacological properties including antioxidant and hepatoprotective activity^{2,3}. The drug CCl₄ is metabolized in endoplasmic reticulum and mitochondria with the formation of CClO₃⁻ the reactive oxidative free radical intermediate generated by cytochrome P-450. The nascent oxygen O⁻ resulted via lipoperoxidation causes rise in intracellular reactive Fe⁺² ions, aldehyde and depletion GSH and calcium sequestration.

Oxidative CClO₃⁻ also by direct covalent interaction induces degeneration of Ca⁺² sequestrations. Silymarin is marketed as one of the standard hepatoprotective herbal formulation. Recently, many folk remedies from plant origin are being evaluated for its possible antioxidant and hepatoprotective effects against different chemical-induced liver damage in experimental animals^{4,5}. *Givotia moluccana* is known as white catamaran tree, plant belongs to Euphorbiaceae family⁶. Bark is brown, smooth, peeling off in thick scales. Leaves are alternate, randed and heart shaped. Ovary is globose, hairy 2-3 celled. Leaves and roots are possess medicinal activity. The plant parts are used as Bark-Rheumatism, Fruit-skin diseases, Seed-dandruff, and psoriasis⁷.

MATERIALS AND METHODS

Materials

Drugs: Carbon tetrachloride, Silymarin and Olive oil were used in this study.

Plant collection

The aerial parts of *Givotia moluccana* was collected during flowering season in the month of March from S.V.University, Tirupathi. The plant was authenticated by Dr. Madhava chetty, Toxonomist, S.V.University, Tirupathi, and voucher specimen was numbered and deposited in our Research lab PRRM.College of pharmacy.

Address for correspondence

D. Sateesh babu*

Department of Pharmacognosy,
P. Rami Reddy Memorial College of Pharmacy,
Kadapa, Andhra Pradesh, India,
E-mail: sateeshbabu386@gmail.com,
Mobile No: +91-9492945311.

Extraction

The coarsely powdered aerial parts were extracted with ethanol by using soxhlet apparatus until the phytoconstituents were completely exhausted. The ethanolic extract was evaporated through rotary evaporator under reduced pressure and labeled.

Phytochemical investigation

Phytochemical analysis of extract was carried out to find out the presence of phytoconstituents viz tannins, glycosides, carbohydrates, flavonoids etc.

Experimental animals

Wistar rats (150-200 g) body weight were obtained from Raghavendra enterprises, Chennai and they were housed under standard husbandry conditions, 23 ± 2°C temperature, 12 h light/dark cycle with standard rat feed with water.

Acute toxicity studies

Acute oral toxicity studies were conducted to determine the LD₅₀ cut off value (mg/kg body weight) as per the OECD 2006 Guideline – 423 and OPTT up and down procedure.

EXPERIMENTAL DESIGN

Assessment of hepatoprotective activity:

A toxic dose or repeated doses of a known hepatotoxin such as carbon tetrachloride, paracetamol, thioacetamide, rifampicin, alcohol, D-galactosamine, allyl-alcohol etc., are administered to induce liver damage in experimental animals^{8,9}. If the hepatotoxicity produced by the toxin is prevented or reduced, then the test substance is considered as an effective hepatoprotective agent^{10,11}. In the present investigation, rats (n=6) were randomized in to following groups and the pharmacological investigation was carried using carbon tetrachloride as inducing agents and the test EEGM at dose levels of 200 and 400 mg/kg as hepatoprotective agent. In experiment the rats are divided into following groups with six animals in each group.

Group I - Saline water per orally 21 days.

Group II- CCl₄ (0.1 ml/kg, p.o) + Olive oil (0.1 ml/kg, p.o) for 21 days.

Group III - CCl₄ (0.1 ml/kg, p.o) + Silymarin (20 mg/kg, p.o) for 21 days.

Group IV - CCl₄ (0.1 ml/kg, p.o) + EEGM (200mg/kg, p.o) for 21 days.

Group V- CCl₄ (0.1 ml/kg, p.o) + EEGM (400mg/kg, p.o) for 21 days.

Treatment with plant extract was started after 24 h of administration of inducing agent. After 21 days of such treatment, rats were sacrificed by cervical dislocation

Biochemical analysis:

Blood was collected and serum was separated by allowing the blood samples to coagulate for 30 min at 37°C followed by centrifugation (300 rpm for 15 min) and subjected for determination of biochemical parameters like serum bilirubin¹², SGPT, SGOT¹².

Liver was dissected out, washed with ice cold phosphate Buffer saline (PBS) (0.1 M, P^H 7.4) and 10% tissue homogenate used for different biochemical analysis. A part of the liver was used for histopathological studies.

STATISTICAL ANALYSIS:

The results are expressed as Mean ± SEM of four animals from each group. The data were evaluated by one-way ANOVA followed by TUKEY 'S' multiple comparison tests. *P values <0.05 was considered statistically significant.

RESULTS

Preliminary Phytochemical screening:

The various Phytoconstituents present in different extracts were given in Table 1. EEGM showed significant amounts of tannins, glycosides, flavonoids and carbohydrates.

Acute toxicity studies:

The EEGM did not exhibit any toxic effects up to 5000 mg/kg body weight on oral administration. Body weight before and after administration were noted and any changes in skin, eyes, mucous membrane, respiratory, circulatory, autonomic, central nervous system, behavioral pattern were observed, sign of tremors, convulsions, salivation, lethargy, sleep and coma were seen. The onset of toxicity and signs of toxicity were not seen in the rats up to 72 h of observation period. This indicates the safety extract.

Biochemical parameters:

Rats treated with CCl₄ showed a significant hepatic damage as observed from elevated levels of hepato-specific enzymes as well as severe alteration in different liver parameters. SGPT, SGOT, and serum bilirubin and ALP in serum were increased in CCl₄ intoxicated control animals. Treatment with the ethanolic extract of *Givotia moluccana* showed significant protection against both CCl₄ induced liver damage against increase in serum enzyme levels and bilirubin in a dose responsive manner. Similarly, LP, SOD, CAT, GSH and glycogen contents were estimated from liver.

Histopathological studies:

Histopathological examination of liver sections of control group showed normal cellular architecture with distinct hepatic cells, sinusoidal spaces and central veins. Disarrangement of normal hepatic cells with centrilobular necrosis, vacuolization of cytoplasm and fatty degeneration were observed in CCl₄ intoxicated animals. The liver sections of the rats treated with aqueous ethanolic extract of *Givotia moluccana* and standard drugs followed by CCl₄ intoxication showed a sign of protection as it was evident the absence of necrosis and vacuoles.

DISCUSSION

Carbon tetrachloride the well known hepato-destructive agents that are widely used to induce acute-toxic liver injury in laboratory animals¹³.

The changes associated with CCl₄-induced hepatic damage are similar to that of acute viral hepatitis¹⁴. The hepatotoxicity of CCl₄ has been reported to be due to its biotransformation by cytochrome P-450 system to produce trichloroethylene free radicals. These free radicals may again react with oxygen to form trichloroethylene peroxy radicals, which exert their action on lipids membrane of endoplasmic reticulum to evoke lipid per oxidation¹⁵. In the present investigation, CCl₄ administration resulted in elevated activities of SGOT, SGPT and ALP in serum against their respective control values. Similarly, serum bilirubin level was also found to be increased significantly as a result of CCl₄ toxicity. On the other hand, total serum protein level was lowered in response to CCl₄ administration when compared with control. Abnormally higher levels of SGPT, SGOT and ALP after CCl₄ administration, that indication of the development of hepatic injury, which is responsible for leakage of cellular enzymes into the blood. When liver plasma membrane gets damaged, a variety of enzymes normally located in the cytosol are released into the circulation. The powdered *Givotia moluccana* aerial parts were subjected to evaluate its total ash, acid insoluble ash, water soluble extractive value, alcohol soluble extractive value, moisture content and phytochemical evaluation.

Oral administration of various doses of EEGM on CCl₄ intoxicated rats resulted in gradual normalization of the activities of SGOT, SGPT and ALP. This evidently suggests the protective effect of the extract in improving the functional integrity of liver cells. Treatment with EEGM significantly decreased the elevated level of total bilirubin in serum towards normally indicating its hepatoprotective efficacy. Decreased total serum protein level in CCl₄ treated rats may be attributed to impaired protein synthesis by damaging liver tissue. Subsequent treatment of CCl₄ intoxicated rats with EEGM increased the total serum protein (TSP) level. This further signifies the curative nature of extract against CCl₄ toxicity. Hepatic lipid peroxidation (LP), expressed as TBARS (thiobarbituric acid reacting substances), increased significantly in CCl₄ toxicity. Enhanced LP and reduced activities of SOD and CAT is an indication of generation of free radical stress as a mark of hepatic damage due to CCl₄ toxicity. Marked reductions in the activities of these free radical scavenging enzymes, SOD and CAT, associated with CCl₄ toxicity were significantly reversed to normal on oral feeding of EEGM in a dose dependent manner conferring the anti-lipid per oxidative ability to the extract. CCl₄ induced damage of hepatocytes is also a reason behind decreased glycogen content of liver tissue. The curative efficacy of EEGM was dose dependent as evidenced by gradual reversal of the SGPT values of various biochemical markers back to normal following oral administration. This may probably be through promotional activation of antioxidant enzymes and regeneration of hepatocytes that restore the structural and functional integrity of liver. The protective effects due to treatment with *Givotia moluccana* extract strongly indicated the possibility of the extract being able to prevent and/or mitigate any leakages of marker enzymes

into circulation, condition the hepatocytes to accelerate regeneration of parenchyma cells, and preserve the integrity of the plasma membranes and hence restore these enzyme levels¹⁶. Thus, the present investigation confirms the hepatoprotective action of EEGM against CCl₄ induced hepatotoxicity in rats.

The effects of ethanolic extract of *Givotia moluccana* on serum enzymes were studied and the results were given. It is well known that CCl₄ is used as a hepatotoxic agent on various animals^{17, 18}. Administration of SGPT, ALP, serum triglycerides and cholesterol in comparison to control group. The EEGM showed a significant decrease in the serum enzymes SGOT, SGPT, and ALP (P<0.001) but also significantly improved the triglycerides and cholesterol level when compared control groups. These raise in GSH content of liver after treatment with EEGM and standard drug silymarin (20 mg/kg, p.o) also exhibited similar results significantly (P<0.001).

Table 1: Qualitative phytochemical determination of active constituents in ethanolic extract of *Givotia moluccana* (EEGM)

Plant constituent	EEGM
Flavonoids	+
Carbohydrates	+
Tannins	+
Glycosides	+
Alkaloids	-
Steroids	-
Saponins	-

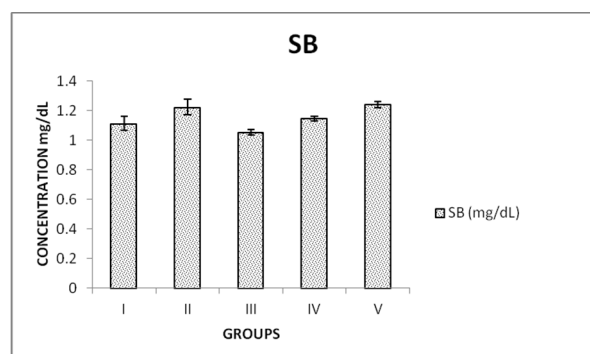
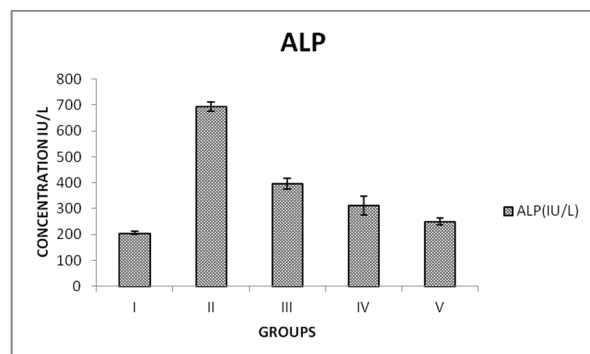
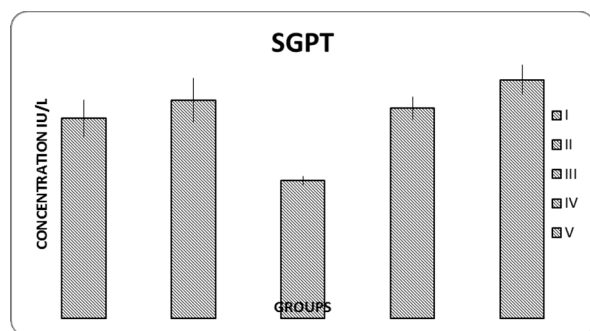
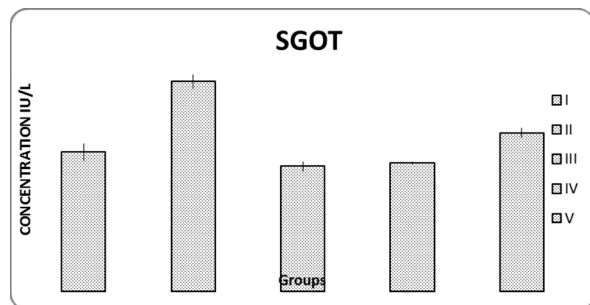
Table 2: Ethanolic extract of *Givotia moluccana* (EEGM) on serum enzymatic activity in CCl₄ induced liver damage in rats (n=6).

Groups	SGOT(IU/L)	SGPT(IU/L)	ALP(IU/L)
I	316.0 ± 19.70	69.25 ± 6.223	205.3 ± 5.85
II	475.3 ± 15.67	75.50 ± 7.643	693.8 ± 18.75
III	283.8 ± 11.02***	47.75 ± 1.548***	395.5 ± 20.95*
IV	291.5 ± 1.936**	72.75 ± 3.860**	311.5 ± 35.50**
V	359.3 ± 10.89*	82.50 ± 5.123*	249.5 ± 12.90***

Table 3:

GROUP	SB (mg/dL)
I	1.113 ± 0.0470
II	1.223 ± 0.0530
III	1.053 ± 0.01702***
IV	1.145 ± 0.01708**
V	1.240 ± 0.01958*

The results are expressed as Mean \pm SEM of four animals from each group. The data were evaluated by one-way ANOVA followed by Tukey's multiple comparison tests. *P values < 0.05 was considered statistically significant. EEGM= ethanolic extract of *Givotia moluccana*.



CONCLUSION:

The scientific research on *Givotia moluccana* suggests a huge antioxidant and hepatoprotective potential of this plant. The high dose *Givotia moluccana* extract, showed better results as compared to low dose, both biochemically and morphologically, and the results were comparable with that of standard drug, silymarin. Purifying the extract and identifying the active principle like flavonoids, phenolic compounds may yield a good hepatoprotective drug. Thus the present study indicates that the ethanolic extract of aerial parts of *Givotia moluccana* may be used an effective hepatoprotective agent.

ACKNOWLEDGEMENT:

We are thankful to Management of P. Rami Reddy Memorial College of Pharmacy, Kadapa, A.P for the providing the all facilities for carried out this work.

REFERENCES:

1. Patel RK, Patel MM, Patel MP, Kanzaria NR, Vaghela KR, Patel NJ. Hepatoprotective activity of *Moringa oleifera* Lam. Fruit on isolated rat hepatocytes, Pharmacognosy Magazine 2008; 4:118-23.
2. DeFeuids FV, Papadopoulos V, Drieu K, *Ginkgo biloba* extracts and cancer a research area in its infancy. Fundam Clin Pharmacol 2003; 17: 405-17.
3. Takeoka GR, Dao LT. Antioxidant constituent of almond (*Prunus dulcis* (Mill.) D.A. Webb) hulls. J Agri Food Chem 2003; 51: 501-496.
4. Ostapowicz G, Fontana RJ, Schiqdt FV, et al. Results of a prospective study of acute liver failure at 17 tertiary care centers in the United states. Ann. Intern. Med. 2002, 947-137.
5. Karan M, Vasisht K, Handa SS. Antihepatotoxic activity of *Swertia chirata* on Carbon tetrachloride induced hepatotoxicity in rats. Phytotherapy Research 1999; 13, 30-24.
6. Baskar ananda raj. V*, Murugamani. V, Mounika. P, Maduri. B, Preliminary phytochemical investigation of *Givotia moluccana* Stem. ISSN: 2229-3701.
7. Baskar ananda raj. V*, Murugamani. V, Anusha. CH, Indraja. N. Preliminary pharmacognostical evaluation of *Givotia moluccana* Leaves. 2012; 4(2); 74-78.
8. Venkateswaran S, Pari L, Viswanathan P, Venugopal PM, Protective effect of liver, a herbal formulation against erythromycin estolate induced hepatotoxicity in rats. J Ethnopharmacology 1997; 57:161.
9. Chatterjee S, Das SN. Uptake of bromsulphalein by liver slices of rat treated with Carbon tetrachloride and a polyherbal formulation Lip-7. Indian Drugs. 1999; 36:140.

10. Rubinstein, D. Epinephrine release and liver glycogen levels after CCl₄ administration. American journal of physiology 1962; 203, 1037-1033.
11. Suja SR, Latha PG, Pushpangadan P, Rajasekharan S, Aphrodisiac property of Helmintho stachys zeylanica in mice. Journal of Tropical Medicinal Plants 2002;(3), 195-191.
12. Mallory HT, Evenlyn EA. The determination of bilirubin with photoelectric colorimeter. J Biol Chem. 1937; 119: 485-481.
13. Henry RJ, Cannon DC, Winkelman JW. Clinical chemistry: principles and techniques. New York;Harper and Row: 1974.
14. Reyes-Gordillo K, Segovia J, Shilbayama M, Vergara P, Moreno MG, Muriel P. Curcumin protects against acute liver damage in the rat by inhibiting NF-KB, proinflammatory cytokines production and oxidative stress. Biochem Biophysic Acta2007; 1770:989-96.
15. Recknagel RO, Glende EA, Dolk JA, Waller RL. Mechanism of carbon tetrachloride toxicity. Pharmacologic Therp1989, 43:54-139.
16. Rafatullah. Hepatoprotective properties of *Commiphora pobalsamum*, a traditional medicinal plant of Saudi Arabia. Drug Exptl. Clin.Res 2004; 30(5/6):2120.
17. Johnson DE, Kroening C, Pharmacol Toxicol 1998; 83:231.
18. Reckangel RO, Trends Pharmacol Sci 1983; 4:129.

How to cite this article:

Sateesh babu D*¹ Yanadaiah JP¹ Lakshman kumar D¹ Siva Sankar Prasad K² Siva Sankar S³: Hepatoprotective activity of Aqueous Ethanolic extract of Aerial parts of *Givotia Moluccana* l. on CCL₄-induced Hepatototoxicity in Rats: 5(3): 1864-1868. (2014)

All © 20104 are reserved by Journal of Global Trends in Pharmaceutical Sciences.