



HEPATOPROTECTIVE ACTIVITY OF ETHANOLIC EXTRACT OF WHOLE PLANT OF *GOMPHRENA SERRATA* AGAINST HEPATOTOXICITY IN RATS

Nandini K N*, Dr. Palaksha M.N, Mamatha B.S, Lekhana A.R

Department of Pharmacology, Bharathi College of Pharmacy, Bharathinagara, Mandya, India

*Corresponding author E-mail: Nandinigowda81@gmail.com

ARTICLE INFO

Key Words

Hepatoprotective, Silymarin, paracetamol, alcohol, *Gomphrena serrata*



ABSTRACT

Present study was to evaluate the hepatoprotective potential of ethanolic extract of the whole plant of *Gomphrena serrata* against paracetamol and alcohol induced hepatotoxicity in rats. In this study, Oral administration of plant extract of *Gomphrena serrata* in two doses 200mg/kg and 400mg/kg body weight were subjected for the evaluation of hepatoprotective potential against paracetamol (2g/kg) and alcohol (5g/kg) induced liver injury. Silymarin (50mg/kg) was used as a standard drug. In both the methods, *Gomphrena serrata* extract (200mg/kg) and (400mg/kg) showed dose dependent significant decrease in SGPT, SGOT, Total bilirubin and Total protein level when compared with toxic control and increase in GSH, SOD, CAT levels. Hepatoprotective effect was also confirmed by histopathological studies of liver which showed less damage in extract treated groups when compared to paracetamol (2g/kg) and alcohol (5g/kg) treated groups were comparable with that of standard. The extract found to have significant hepatoprotective activity in both; paracetamol and alcohol induced hepatic injury models. Biochemical and histopathological studies have revealed that this plant have comparable hepatoprotective activity with that of Silymarin. It leads to the conclusion that the *Gomphrena serrata* plant extract can be utilized for its hepatoprotective activity.

INTRODUCTION

Liver is one the most important organ concerned with the biochemical activities in the human body. Acute liver failure is one of the most common problems following drug intoxication and paracetamol toxicity is responsible for 20–70% of cases of acute live failure.¹⁻² It is the major site of xenobiotic metabolism and its injury can be caused by toxic chemicals, drugs, and virus infiltration from ingestion or infection. During the detoxification, reactive oxygen species (ROS) are generated within hepatocytes that result in oxidative damage, gross cellular changes and cell death causing

hepatotoxicity or liver damage. In the absence of a reliable liver protective drug in the modern system of medicine, a number of medicinal preparations in Ayurveda, the Indian system of medicine, are recommended for the treatment of liver disorders. Natural remedies from medicinal plants are considered to be effective and safe alternative treatments for hepatotoxicity³. Paracetamol is also called as acetaminophen. It is used as an analgesic and antipyretic agent. The healing dose of paracetamol is more secure however it's over dose is also considered because of its narrow healing

index. Its over dose can result in hepatic and renal toxicity in human beings and experimental animal.⁴ Paracetamol is metabolized mainly in the liver to nontoxic major metabolites, such as glucuronic acid–sulphate conjugates, and excreted in the urine. Only a small amount of Paracetamol is converted by the hepatic cytochrome P450 (CYP) enzyme system (CYP 2E1 and CYP 1A2 isoenzymes) into the reactive hepatotoxic substance N-acetyl-para-benzoquinone imine (NAPQI).⁵ This metabolite is a highly reactive electrophilic molecule, which covalently binds to intracellular proteins and leads to damage in liver parenchymal cells. Alcoholic liver disease continues to be one of the most serious liver disorders throughout the world. The liver disease seen in alcoholises compasses three main related entities, namely steatosis, alcoholic hepatitis and cirrhosis. Steatosis (fatty liver) is the initial histological manifestation of alcoholic liver diseases and found in 70–100% of all patients taking excessive amounts of alcohol.⁶ Modern medicines have little to offer for mitigation of hepatic diseases and it is chiefly the plant based preparations, which are employed for the treatment of liver disorders. There are few drugs available for the treatment of liver disorders. In view of this, the present study was undertaken to investigate the hepatoprotective activity of *Gomphrena serrata* whole plant of ethanol extract against paracetamol and alcohol induced hepatotoxicity in rats.

MATERIALS AND METHODS

Plant material: The fresh whole plants of *Gomphrena serrata* was collected from the local area of Bharathinagara, Mandya District, Karnataka. The plant were identified and authenticated by Botanist Dr. Gurukar Mathews, Head of the Department of Botany, Bharathi College of Post Graduation and Research Centre, Bharathinagara, Maddur (Tq), Mandya (Dist), Karnataka state.

Preparation of extract: After the collection of whole plant of the *Gomphrena serrata* was cut in to small pieces and shade dried.

The dried whole plant of *Gomphrena serrata* was then pulverized separately into coarse powder by a mechanical grinder. The extract of 100g of powdered plant of *Gomphrena serrata* was carried out by hot extraction process by using Soxhlet apparatus with ethanol was used as solvent for 72 hours at 50°C. The extract was air dried at 25–30°C and weighed 100g of powdered plant of *Gomphrena serrata* yields 9.6g of dried extract.

Phytochemical screening: The phytochemical test was carried out according to the standard procedure indicates the presence of alkaloids, carbohydrates, flavonoids, tannins, etc⁷

Experimental animals: Healthy Wistar albino rats (150–180g) of either sex were used for the experiment were procured from the animal house of Bharathi college of pharmacy, Bharathinagara, Karnataka (1135/PO/RE/S/07/CPCSE). They were maintained under standard conditions (temperature 22±2°C, relative humidity 60±5% and 12 h light/dark cycle). The animals were housed in sanitized polypropylene cages containing sterile paddy husk as bedding. They had free access to food and water ad libitum. The Institutional Animal Ethics Committee approved the experimental protocol (Approval no. BCP/IAEC/PCOL/03/2019)

Acute toxicity studies: An acute toxicity study was carried out in order to check the toxic effects for ethanolic extract of whole plant of *Gomphrena serrata* on female mice (This is because literature surveys of conventional LD₅₀ testes shows that generally female were slightly more sensitive and single sex of animals is used in order reduced variability and means of minimizing the number of animals used). The study was performed as per Organization for Economic Cooperation and Development (OECD) and acute oral toxicity was done by up and down procedure (OECD guideline – 425)⁸

Assessment of hepatoprotective activity

Paracetamol induced hepatotoxicity^{9,10}

Animals are divided into five different groups, each having 6 rats and treated accordingly. Group I: control received 0.3% CMC (2ml/kg) for 10 days, Group II: Toxic control (2gm/kg,p.o) at every 72 hours for 10 days, Group III: Received Silymarin 50mg /kg P.O. for 10 days along with paracetamol (2gm/ kg) for every 72 hrs, Group IV and V : Received *Gomphrena serrata* (200mg/kg and 400mg/kg p.o respectively 10 days and simultaneously administered paracetamol 2gm/kg body weight P.O, every 72 hours. On 10th day Animals are sacrificed by anesthesia; blood was collected through cardiac puncture and analyzed for various biochemical parameters. Further liver was dissected out and used for Histopathological studies.

Ethanol induced hepatotoxicity¹¹

Animals are divided into five different groups, each having 6 rats and treated accordingly. Group I: Treated with vehicle alone 0.3% CMC (2ml/kgb.w.p.o) daily for 10 days. Group II: Toxic control treated with vehicle 0.3% CMC (2ml/kgb.w.p.o) daily for 10 days followed by ethanol intoxication on the 10th day. Group III, IV, V were treated with Silymarin (50 mg/kg b.w.p.o), *Gomphrena serrata* (200mg/kg b.w.p.o), *Gomphrena serrata* (400 mg/kg b.w.p.o) daily for ten days followed by ethanol intoxication on 10th day. At the end of the 10th day, food was discontinued and the rats in all groups except control group received, an acute oral dose of ethanol (5g/kg,b.w) diluted with distilled water (6:4v/v) by gavages .The blood and liver samples were collected 18hr after administration of ethanol under anesthesia, were analyzed for various biochemical parameters and Histopathological studies.

Evaluation: The SGOT, SGPT, Total bilirubin and Total protein estimated in the present study from the blood serum of animal by using biochemical enzymatic kits as marker of liver injury.

Estimation of oxidative stress:

Animals were sacrificed the liver tissue is washed thoroughly and rinsed with ice .They were gently blotted between the folds of a filter paper and weighed in an analytical balance. 10% homogenate was prepared in 0.05M phosphate buffer (pH 7) using a homogenizer at 4°C. The homogenate was centrifuged at 3000 rpm for 10min . The supernatant was used for the estimation of GSH, SOD and Catalase.

Glutathione: The Sufhydryl group of glutathione reacts with DTNB (5, 5 - dithiobis-2-nitro benzoic acid) which produces a yellow colored 5-thio-2-nitrobenzoic acid (TNB) compound. Measurement of the absorbance of TNB at 412 nm provides an accurate estimation of glutathione in a sample. Briefly, 0.5 ml of homogenate was mixed with 0.1 ml of 25% TCA to precipitate proteins and centrifuged at 4000 rpm for 5 min. The 0.3 ml of the supernatant was mixed with 0.5 ml of 0.1M phosphate buffer (pH 7.4) and 0.2 ml of 10 mM DTNB. This mixture was incubated for 10 min and the absorbance was measured at 412 nm against appropriate blanks. The glutathione content was calculated by using extension coefficient $13.6 \times 10^4 \text{M}^{-1} \text{cm}^{-1}$. The values are expressed as units /mg protein. 1 unit of enzyme is the amount necessary to decompose 1 μ mole of NADPH per minute.¹²

GSH = $\Delta \text{Abs at } 412 \text{ nm} / 13.6 \times 10^{-3} \times \text{total protein} \times \text{total volume}$

Super oxide dismutase: 0.01ml of the tissue homogenate was mixed with 0.2 ml of 0.1M EDTA (containing 0.0015% NaCN), 0.1ml of 1.5mM NBT and phosphate buffer(67mM,pH7.8) In a total volume of 2.6ml. After adding 0.05ml of riboflavin, The absorbance of the Solution was measured against distilled water at 560nm using UV spectrophotometer. All the tubes were illuminated uniformly for 15min and absorbance of the blue colour Formed was measured again. Percent of inhibition was calculated after comparing .Absorbance of sample with the absorbance of control (the tube containing no enzyme activity).The volume of the sample required to scavenge

50% of the generated superoxide an ion was considered as a unit of enzyme activity and expressed in U/mg Protein. The % inhibition of the sample is calculated using the following formula.^{13,14}

$$\% \text{inhibition} = \frac{\text{Absorbance of test} - \text{Absorbance of blank} \times 100}{\text{Absorbance of test}}$$

Catalase:

The catalase activity was assayed by H₂O₂ decomposition method. In the incubation mixture 0.1ml of sample, 1.9 ml of 0.5 M phosphate buffer and 1ml of 11mM of H₂O₂ solution was added to initiate the reaction, and the absorbance was measured immediately at 0, 1, 2 mins at 240 nm. Control/blank was 0.1ml sample and 2.9 ml of phosphate buffer. Activity of catalase was calculated using the mmoles(mM) extinction coefficient 40cm-1.µmoles of H₂O₂ decomposed/min/mg protein.^{15,16}

$$\text{Catalase(U/mgprotein)} = \frac{\Delta A/\text{min} \times 1000 \times 3}{40 \times \text{mg protein in sample}}$$

Histopathological Examination:

Histopathological section was done by fixing liver tissues in 10% formalin for 24h. The formalin fixed specimens were embedded in paraffin and section (3-5µm) and stained with haematoxylin and eosin dye. The histochemical sections were evaluated by light microscopy.

STATISTICAL ANALYSIS

All data were expressed as mean ±SEM. The statistical significance between groups was compared using one way ANOVA, followed by Dunnett's (multiple comparisons) test.

RESULTS

Hepatoprotective activity of *Gomphrena serrata* on paracetamol induced hepatic damage in rats: The effect of ethanolic extract of whole plant extract of *Gomphrena serrata* on various biochemical parameters are shown in table No.1

Group I (control): The SGPT, SGOT, Total bilirubin and Total protein level were 93.12±0.346, 85.06±0.6561,

0.938±0.014, 6.867±0.2517 respectively,

Group II : The paracetamol induced group showed elevation in SGPT, SGOT, Total bilirubin and Total protein level up to 157.1±0.2336, 139.6±0.4645, 3.518±0.129, 3.663±0.0767 respectively,

Group III: The SGPT, SGOT, Total bilirubin and Total protein level were 94±0.4299, 96.59±1.068, 1.310±0.0339, 6.980±0.1402 respectively after treatment with Silymarin (50ml/kg).

Group IV: There was a reduction in the SGPT, SGOT, Total bilirubin and Total protein level (152.9±0.3465, 134.4±2.037, 3.212±0.05224, 4.598±0.1360) after the treatment with 200mg/kg of *Gomphrena serrata* plant extract.

Group V: There was a reduction in the SGPT, SGOT, Total bilirubin and Total protein level (152.9±0.3465, 134.4±2.037, 3.212±0.05224, 4.598±0.1360) after treatment of with 400 mg/kg *Gomphrena serrata* plant extract.

Evaluation of liver antioxidant enzymes

Table No.2 and Fig 2 shows the effect of extract of *Gomphrena serrata* on SOD, GSH, CAT concentration in rat liver after challenging with paracetamol. It was observed that treated with paracetamol developed a hepatic damage, decrease in SOD, GSH and CAT when compared to normal control. Animal treated with standard (Silymarin) shows extremely significant and increase in GSH, CAT, SOD. The *Gomphrena serrata* (200mg/kg) treated animals shows significant and increase in liver antioxidant. *Gomphrena serrata* (400mg/kg) treated animals shows moderately significant and increasing in GSH, CAT, SOD.

Hepatoprotective activity of *Gomphrena serrata* on alcohol induced hepatic damage in rats: The effect of ethanolic extract of whole plant extract of *Gomphrena serrata* on various biochemical parameters are shown in table No.3

Group I (control): The SGPT, SGOT, Total bilirubin and Total protein level were 45.03 ± 0.752 , 102.6 ± 0.515 , 0.791 ± 0.019 , 7.727 ± 0.12 respectively,

Group II : The ethanol induced group showed elevation in SGPT, SGOT, Total bilirubin and Total protein level up to 109.7 ± 0.845 , 185.9 ± 0.627 , 4.023 ± 0.132 , 4.788 ± 0.09 respectively,

Group III: The SGPT, SGOT, Total bilirubin and Total protein level were 67.03 ± 0.971 , 121.1 ± 0.444 , 1.630 ± 0.068 , 1.630 ± 0.068 , 6.707 ± 0.07 respectively after treatment with Silymarin (50mg/kg).

Group IV: There was a reduction in the SGPT, SGOT, Total bilirubin and Total protein level (96.81 ± 0.717 , 164.9 ± 1.023 , 3.120 ± 0.094 , 4.345 ± 0.03) after the treatment with 200mg/kg of *Gomphrena serrata* plant extract .

Group V: There was a reduction in the SGPT, SGOT, Total bilirubin and Total protein level (86.37 ± 0.466 , 148.5 ± 0.475 , 1.765 ± 0.116 , 5.592 ± 0.07 respectively) after treatment of with 400 mg/kg *Gomphrena serrata* plant extract.

Evaluation of liver antioxidant enzymes:

Table no 4 and Graphs fig5 Shows the effects of extracts of *Gomphrena serrata* on SOD, CAT and GSH concentration in rat liver after challenging with alcohol developed a hepatic damage observed that decrease in SOD, CAT and GSH when compared to control animals treated with standard (Silymarin) showed significant increase in SOD, CAT and GSH. *Gomphrena serrata* extract (200mg/kg) treated animals shows significant increase in SOD, CAT and GSH as compared to toxic control. *Gomphrena serrata* (400mg/kg) treated animals shows significant increase in SOD, CAT and GSH.

DISCUSSION:

The present study was under taken to

evaluate the hepatoprotective activity of *Gomphrena serrata* plant extract. The present study was conducted by using two models such as paracetamol and alcohol induced hepatotoxicity. The parameters used for the assessment of hepatoprotective activity was serum enzymes estimations like SGPT, SGOT, Total protein, Total bilirubin, antioxidant activity like CAT, SOD and GSH level and histopathological studies. Administration of paracetamol elevated the Serum levels of SGPT, SGOT, Total bilirubin and Total protein are significantly. The paracetamol is normally eliminated mainly as sulphate and glucuronid. only 5 % of the paracetamol is converted into N-acetyl -P - benzoquinineimine. Beyond administration of toxic dose of paracetamol, the sulfation and glucuronidation routes it become saturated and higher percentage of paracetamol molecules are oxidized to reactive N- acetyl p- benzoquinineimine (NAPQI) by cytochrome 450 enzymes.

The hepatotoxic effect of paracetamol was also confirmed by histopathological studies are showed portal tract inflammation. The Pre-treatment with *Gomphrena serrata* plant extract was able to prevent the elevation of SGPT, SGOT, Total protein and Total bilirubin by paracetamol. Paracetamol inhibits glutathione peroxidase; decrease the activity of catalase, superoxide dismutase, along with increase in levels of glutathione in liver. These biochemical effects may be due to the inhibitory effects on cytochrome P450 and promotion of its glucuronidation. This was also confirmed by histopathological studies. The histopathological observation in paracetamol treated group showed severe necrosis, with accumulation of measured binding with disappearance of nuclei. This as it may be due to the formation of highly reactive radical because of oxidative threat caused by paracetamol. All those changes were very much reduced Histopathological in groups treated with Silymarin *Gomphrena serrata* 200mg/kg and 400 mg/kg.

Table 1: Effect of ethanolic extract of whole plant of *Gomphrena serrata* on SGOT, SGPT, Total protein and Total Bilirubin in Paracetamol induced liver toxicity.

Groups	Treatment	SGOT (U/L)	SGPT (U/L)	Total protein (g/dl)	Total bilirubin (mg/dl)
Control vehicle	0.3% CMC 2ml/kg p.o	85.06±0.6561	93.12±0.346	6.867±0.2517	0.938±0.014
Toxic Control	Paracetamol 2g /kg p.o	139.6±0.4645 ^a	157.1±0.2336 ^a	3.663±0.0767 ^a	3.518±0.129 ^a
Standard	Silymarin 50mg/kg p.o	96.59±1.068* **	94.94±0.4299* **	6.980±0.1402* **	1.310±0.0339* **
Low dose	<i>Gomphrena serrata</i> 200 mg/kg p.o	134.4±2.037*	152.9±0.3465* **	4.598±0.1360* *	3.212±0.05224 *
High dose	<i>Gomphrena serrata</i> 400 mg/kg p.o	119.0±1.542* **	138.7 ±0.2112***	5.810±0.2667* **	2.608±0.1015* **

All the values are Mean±SEM, n=6. One way ANOVA followed by Dunnett's t test. ^ap<0.001 when compared with vehicle treated control group. *p<0.05, **p<0.01, ***p<0.001 when compared with toxic control.

Figure 1: Effect of ethanolic extract of whole plant of *Gomphrena serrata* on SGOT, SGPT, Total protein and Total Bilirubin in Paracetamol induced liver toxicity.

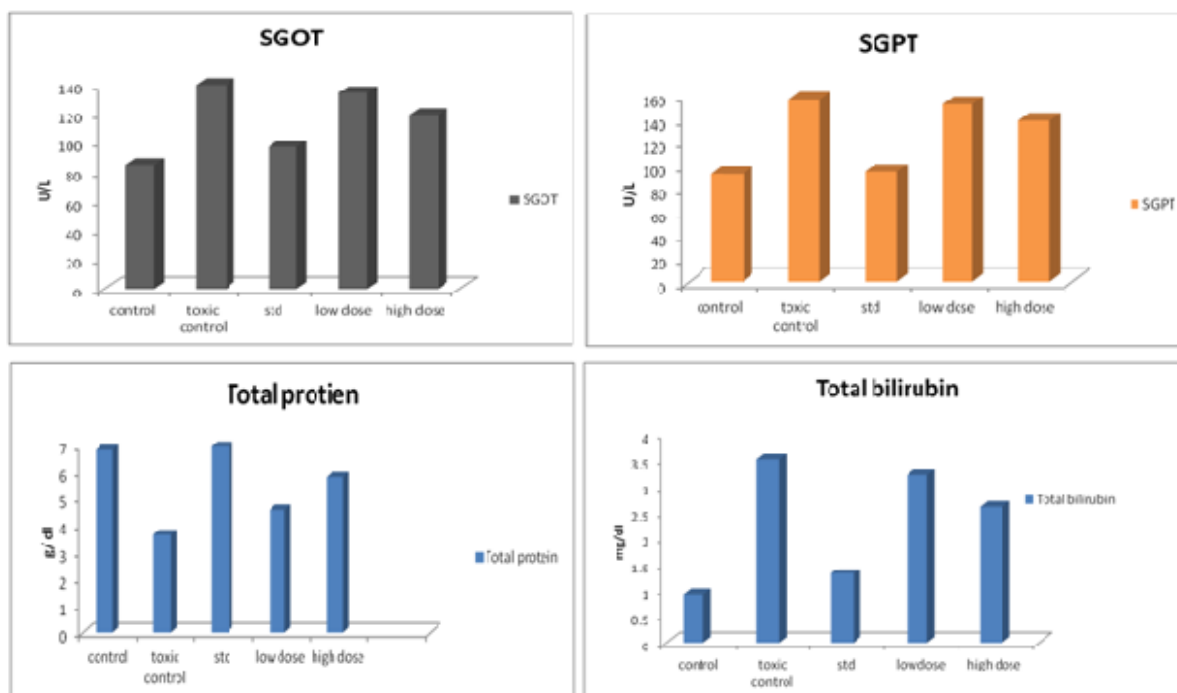


Table 2: Effect of ethanolic extract of whole plant of *Gomphrena serrata* on GSH, CAT and SOD, in Paracetamol induced liver toxicity.

Groups	Treatment	GSH (U/mg)	CAT (U/mg)	SOD (U/mg)
Control vehicle	0.3% CMC 2ml/kg p.o	16.23±0.1082	64.25±0.2161	11.30±0.0784
Toxic Control	Paracetamol 2g/kg p.o	11.77±0.1112 ^a	46.38±0.1626 ^a	6.812±0.1040 ^a
Standard	Silymarin 50mg/kg p.o	17.41±0.1482***	64.73±0.3522***	9.587±0.07159***
Low dose	<i>Gomphrena serrata</i> 200 mg/kg p.o	12.69±0.2670***	56.65±0.544***	7.662±0.1202***
High dose	<i>Gomphrena serrata</i> 400 mg/kg p.o	16.84 ±0.3870***	60.48±1.198***	8.137±0.1515***

All the values are Mean±SEM, n=6. One way ANOVA followed by Dunnett's t test, ^ap<0.001 when compared with vehicle treated control group. *p<0.05, **p<0.01, ***p<0.001 when compared with toxic control.

Fig2: Effect of ethanolic extract of whole plant of *Gomphrena serrata* on GSH, CAT and SOD, in Paracetamol induced liver toxicity.

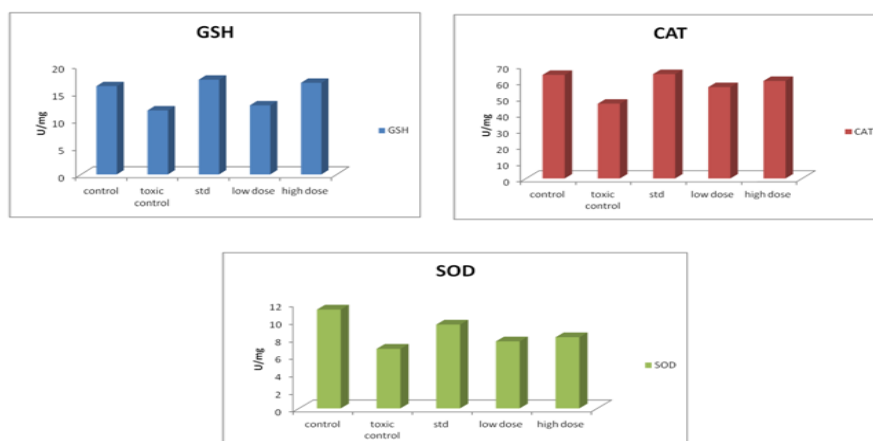
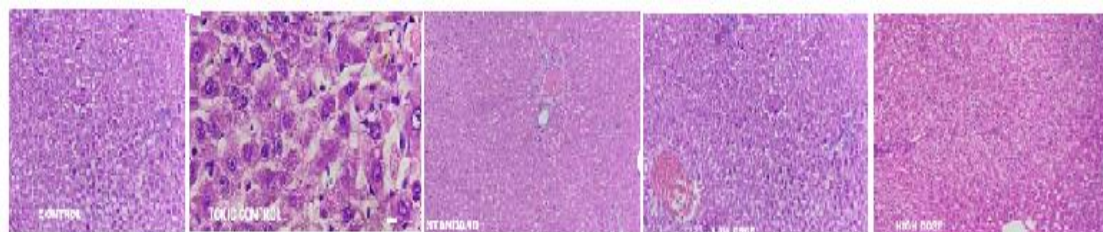


Fig3: Effect of ethanolic extract *Gomphrena serrata* on liver histology in paracetamol induced liver toxicity.



Hepatoprotective activity of *Gomphrena serrata* on alcohol induced hepatic damage in rats .

Table 3: Effect of ethanolic extract of whole plant of *Gomphrena serrata* on SGOT, SGPT, Total protein and Total Bilirubin in ethanol induced liver toxicity.

Groups	Treatment	SGOT (U/L)	SGPT (U/L)	Total protein (g/dl)	Total bilirubin (mg/dl)
Control vehicle	0.3% CMC 2ml/kg p.o	102.6±0.515	45.03±0.752	7.727±0.12	0.791±0.019
Toxic Control	Alcohol 5g/kg p.o	185.9±0.627 ^a	109.7±0.845 ^a	4.788±0.09 ^a	4.023±0.132 ^a
Standard	Silymarin 50mg/kg p.o	121.1±0.444 ^{***}	67.03±0.971 ^{***}	6.707±0.07 ^{***}	1.630±0.068 ^{***}
Low dose	<i>Gomphrena serrata</i> 200 mg/kg p.o	164.9±1.023 ^{***}	96.81±0.717 ^{***}	4.345±0.03 ^{**}	3.120±0.094 ^{***}
High dose	<i>Gomphrena serrata</i> 400 mg/kg p.o	148.5±0.475 ^{***}	86.37±0.466 ^{***}	5.592±0.07 ^{***}	1.765±0.116 ^{***}

All the values are Mean±SEM, n=6. One way ANOVA followed by Dunnett's t test. ^ap<0.001 when compared with vehicle treated control group. *p<0.05, **p<0.01, ***p<0.001 when compared with toxic control.

Figure 4: Effect of ethanolic extract of whole plant of *Gomphrena serrata* on SGOT, SGPT, Total protein and Total Bilirubin in Paracetamol induced liver toxicity.

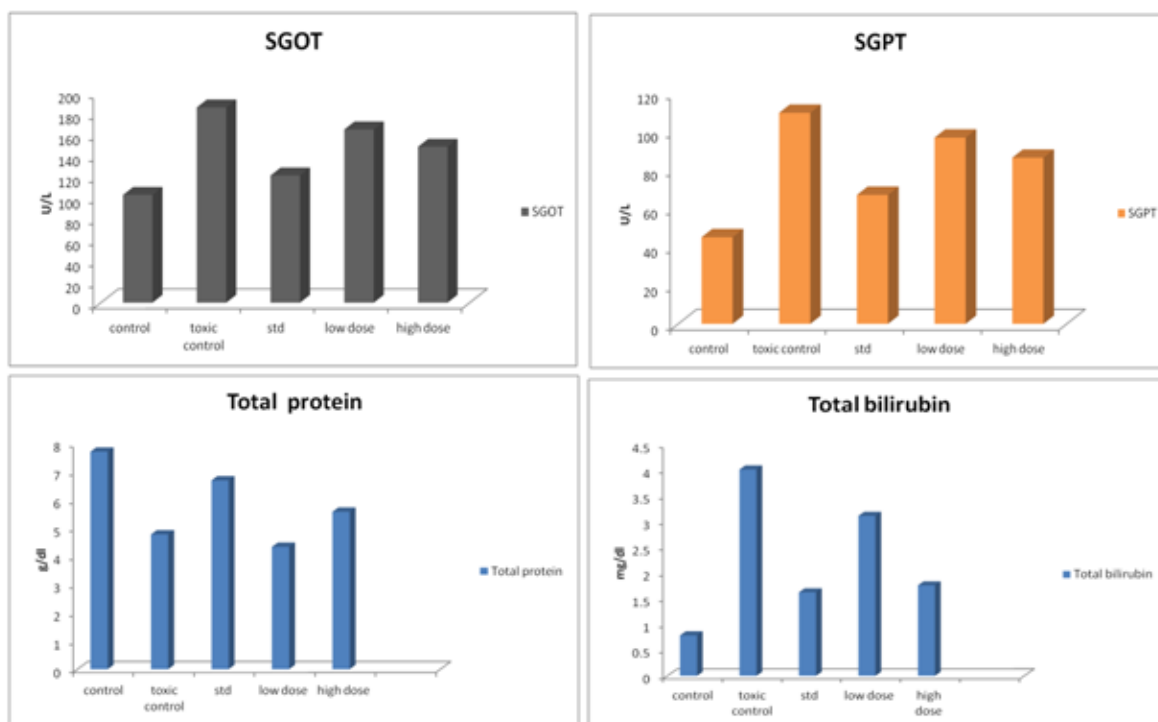


Table 4: Effect of ethanolic extract of whole plant of *Gomphrena serrata* on GSH, CAT and SOD in ethanol induced liver toxicity.

Groups	Treatment	GSH (U/mg)	CAT (U/mg)	SOD (U/mg)
Control vehicle	0.3%CMC 2ml/kg p.o	11.63±0.1306	78.30±0.437	9.397±0.170
Toxic Control	Alcohol 5g/kg p.o	9.710±0.0832 ^a	38.75±0.249 ^a	6.830±0.102 ^a
Standard	Silymarin 50mg/kg p.o	12.75±0.089***	62.00±0.6170***	8.745±0.1065***
Low dose	<i>Gomphrena serrata</i> 200 mg/kg p.o	11.34±0.1139***	35.27±0.2140***	7.632±0.0975***
High dose	<i>Gomphrena serrata</i> 400 mg/kg p.o	12.49±0.0377***	45.70±0.778***	7.430±0.1543*

All the values are Mean ± SEM, n=6. One way ANOVA followed by Dunnet's t test. ^ap<0.001 when compared with vehicle treated control group. *p<0.05, **p<0.01, ***p<0.001 when compared with toxic control.

Fig5 : Effect of ethanolic extract of whole plant of *Gomphrena serrata* on GSH, CAT and SOD, in Paracetamol induced liver toxicity.

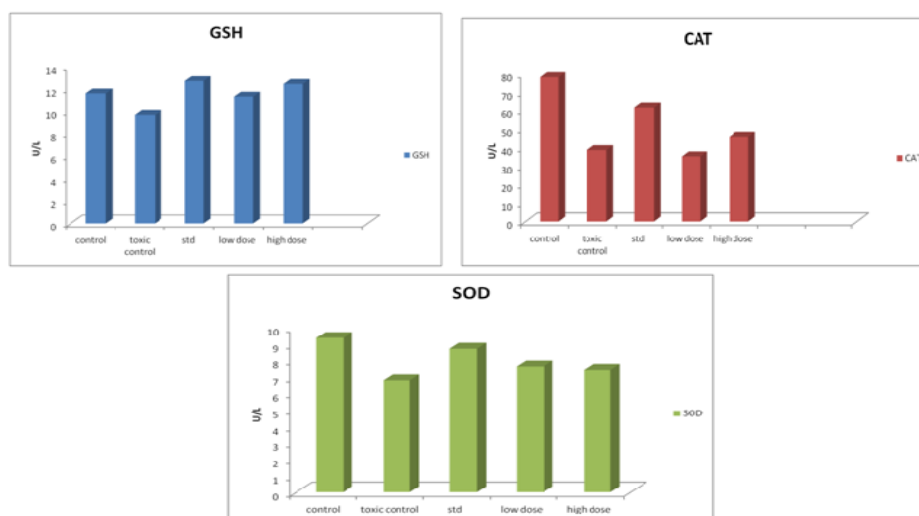
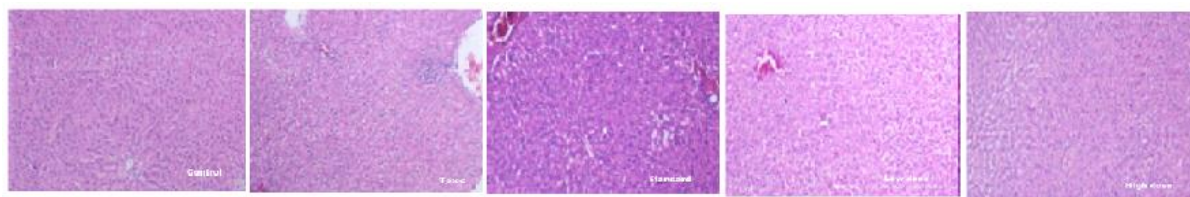


Fig6: Effect of ethanolic extract *Gomphrena serrata* on liver histology in paracetamol induced liver toxicity.



Based on the above results. It could be concluded that *Gomphrena serrata* extracts significant hepatoprotective against paracetamol induced. Administration of Alcohol elevated the Serum levels of SGPT, SGOT, Total bilirubin and Total protein are significantly. Alcohol is the most important and commonly used hepatotoxic agents in the experimental study of liver-related disorders. The most of the hepatotoxic effects produced by alcohol, due to its active metabolite trichloromethyl radical. The macromolecules are covalently bind to the activated radicals and that induces peroxidative degradation of lipid membrane of endoplasmic reticulum rich in polyunsaturated fatty acids. This process cause excessive formation and accumulation of lipids in tissues such as the liver. Lipids from peripheral adipose tissue are translocated to the liver for accumulation^{17,18} Oxidative stress is one major factor in etiology of ethanol injury, mainly by Kupffer cell derived ROS. Ethanol activates Kupffer cells primarily through the action of a substance called endotoxin, which is released by certain gram-negative bacteria present in the intestine. Kupffer cell activation generates ROS and proinflammatory cytokines (TNF alpha, IL-1_β), both of them can lead to liver damage. This study is confirmed that the protective effect of *Gomphrena serrata* against the ethanol induced hepatotoxicity. *Gomphrena serrata* plant extract was able to prevent the elevation of SGPT, SGOT, Total protein and Total bilirubin by ethanol. The Ethanol inhibits glutathione peroxidase that leads to decrease in the activity of catalase, superoxide dismutase, along with increase in levels of glutathione in liver. This was also confirmed by histopathological studies. The histopathological observation in ethanol treated group showed severe necrosis, with accumulation of measured binding with disappearance of nuclei. This as it may be due to the formation of highly reactive radical because of oxidative threat caused by ethanol. All those changes were very much reduced Histopathological in groups treated with Silymarin *Gomphrena serrata* 200mg/kg and 400 mg/kg. Based on the

above results. It could be concluded that *Gomphrena serrata* extracts significant hepatoprotective against ethanol induced. Histopathological studies of liver, treated with alcohol alone revealed the affected architecture of liver parenchyma with damaged hepatocytes. Treatment with whole plant of *Gomphrena serrata* (200mg/kg & 400 mg/kg) revealed significant improvement in architecture of liver parenchyma towards normal and regenerating hepatocytes indicating hepatoprotection. The standard drug Silymarin showed extremely significant reduction in serum biomarkers and endogenous enzyme level. Recent studies have shown that many flavonoids and related polyphenols contribute significantly to the total antioxidant activity of many plant extracts. Natural antioxidants from the plant extracts provide a measure of production of radical scavengers that slows the process of oxidative damage; further previous report indicates that the *Gomphrena serrata* plant extract proved for its potential antioxidant properties. The present study revealed that the *Gomphrena serrata* plant extract have proved its synergistic antioxidant effects of bioactive constituents for observed hepatoprotective activity.

CONCLUSIONS

The present study was undertaken to assess the hepatoprotective activity of *Gomphrena serrata* plant extract. The extract found to have significant hepatoprotective activity in both; paracetamol and alcohol induced hepatic injury models. Biochemical and histopathological studies have revealed that this plant have comparable hepatoprotective activity with that of Silymarin. It leads to the conclusion that the *Gomphrena serrata* plant extract can be utilized for its hepatoprotective activity. Further studies are needed to isolate and characterize the active principles and to find out the mechanism responsible for its hepatoprotective activity.

REFERANCES

- 1 Sherlock, J. Disease of the liver and biliary system, 10th ed. Oxford: Balckwell Scientific Publications, 1997, pp. 103–117.
- 2 Mutimer DJ. Serious paracetamol poisoning and the results of liver transplantation. Gut 1994; 35: 809–814.
- 3 S. Rajeshkumar, (2015). Phytochemical screening and hepatoprotective efficacy of leaves extracts of *annona squamosa* against paracetamol induced liver toxicity in rats. Int. J. Pharmacognosy, **2**: 178-185.
- 4 Varghese . Nephroprotective activity of *Benincasa hispida* (Thunb.) Cogn. fruit extract against paracetamol induced nephrotoxicity in rats. Research Journal of Pharmaceutical Biological and Chemical Science. 2013;4(1):322-32.
- 5 Bessems. Paracetamol (acetaminophen)-induced toxicity: molecular and biochemical mechanisms, analogues and protective approaches. Crit Rev Toxicol 2001; 31: 55–138.
- 6 Jafri MA, Hepatoprotective activity of leaves of *Cassia occidentalis* against paracetamol and ethyl alcohol intoxication in rats. Journal of Ethnopharmacology. 1999 Sep 1;66(3):355-61.
- 7 Nandini Preliminary Phytochemical Analysis and Antioxidant Activities of Ethanol Extract from *Gomphrena serrata* Whole plant. Borneo Journal of phramacy. 2020:Vol 3 issue1,feb 2020,1-14.
- 8 OECD. Guidance, Document on acute oral toxicity, in :Environmental Health and Safety Monograph Series on Testing and Assessment, vol.24,2001.
- 9 Basu SK, Rupesh Kumar M, Kavitha K. Hepatoprotective and antioxidant activity of *Andrographis echiodes* on acetaminophen induced hepatotoxicity in rat . Journal biological science 2009;9(4):351-6.
- 10 Kallappa,. Evaluation of hepatoprotective activity of aqueous extract of *Azadirachta indica* (Neem) leaves against Paracetamol induced Hepatotoxicity in albino rats. Pharmacology online. 2011; (2): 96-108.
- 11 Divya B, Praneetha P, Swaroopa Rani V, Ravi Kumar B. Hepatoprotective effect of whole plant extract Fraction of *Marsilea minuta* line. Asian journal of pharmaceutical and Clinical Research. 2013; 6(3):100-107.
- 12 Moron MS, Depierre JW, Mannervik B. Levels of glutathione, glutathione reductase and glutathione S-transferase activities in rat lung and liver. Biochimica et biophysica acta (BBA)-general subjects. 1979 ;582(1):67-78.
- 13 Paoletti, sensitive spectrophotometric method for the determination of superoxide dismutase activity in tissue extracts. Analytical biochemistry. 1986 ;154(2):536-541.
- 14 Roger walker and Clive Edwards. Clinical Pharmacy and Therapeutics. Churchill Living Stone, 1999; (2):135.
- 15 Li Y, Schellhorn HE. Rapid kinetic microassay for catalase activity. Journal of biomolecular techniques: JBT. 2007;18(4):185.
- 16 Sinha Colorimetric assay of catalase. Analytical biochemistry. 1972; 47 (2):389-94.
- 17 .Monzoni A, Genetic determinants of ethanol-induced liver damage. Mol Med 2001;7(4):255-62.
- 18 Rajalingam D, Varadharajan R, Palani S. Evaluation of hepatoprotective and antioxidant effect of *Combretum albidum* g. Don against ccl4 induced hepatotoxicity in rats. Int J Pharm Pharm Sci 2016;8(9):218-23.