



## SCRUB TYPHUS: A CASE REPORT

Kethamsetty Rohini\*<sup>1</sup>, Jolapuram Harinatha Reddy<sup>1</sup>, L Reddenna<sup>1</sup>,

Y Hrushikesh Reddy<sup>1</sup>, P Venkatesh<sup>1</sup>

<sup>1</sup>Department of Pharmacy practice, Jagan's college of Pharmacy, Nellore,  
Andhra Pradesh-524346, India

\*Corresponding author E-mail: kethamsettyrohini@gmail.com

### ARTICLE INFO

#### Key Words

Eschar; infected chigger;  
infectious illness;  
Orientia tsutsugamushi;  
Scrub typhus



### ABSTRACT

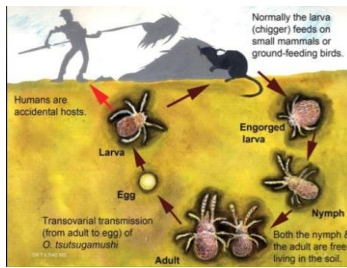
Scrub typhus is a discriminating, febrile, infectious illness caused by an *Orientia tsutsugamushi*. It is anticipated that about 1 million cases of scrub typhus occur annually. It is transmitted to humans through the bite of an infected chigger. It is endemic in southern states of Andhra Pradesh and normally an infection of rural villages and suburban areas. Many laboratory tests can assist in diagnosing scrub typhus, including general and specific tests. Early initiation of treatment based on clinical suspicion. The suggested treatment is doxycycline twice daily orally for 7 to 14 days based on the severity of the disease. We report two cases of scrub typhus from Nellore, Andhra Pradesh.

### INTRODUCTION:

Scrub typhus is a discriminating, febrile, infectious illness caused by an obligate intracellular gram-negative bacterium (*Orientia tsutsugamushi*). It was initially recognized as one of the tropical rickettsial diseases. The phrase scrub typhus derives from the terrain between woods and clearings that harbors the vector and also be prevalent in mountain deserts, sandy beaches and equatorial rain forests. It is frequently acquired during agricultural or occupational exposures because active rice fields are an imperative reservoir for transmission. Working with bare hands, working in short sleeves posed the maximum risks and maintenance work clothes off the grass, wearing a long-sleeved shirt while working showed defensive associations. It is anticipated that about 1 million cases of scrub typhus occur annually. <sup>[1]</sup> It is transmitted to humans through the bite of an infected chigger. Wild rats serve as the likely reservoir for the chiggers and

symbolize a risk factor for human infection. The chigger is only active between July and September (rainy season). Humans accomplish this when an infected chigger bites them while feeding and inoculates *O. tsutsugamushi* pathogens. It is generously grows in the cytoplasm of infected cells. The bacteria reproduce at the inoculation site, and a papule forms that ulcerates and evolving into an eschar with generalized lymphadenopathy (within a few days) and acute febrile illness (within 8-10 days of the chigger bite). As in rickettsial diseases, perivasculitis of the small blood vessels and basic histopathologic lesions recommend that macrophages resulting in the development of serious complications. <sup>[2]</sup> It is endemic in southern states of Andhra Pradesh and normally an infection of rural villages and suburban areas. Majority cases are undiagnosed and prospective studies disclose incidence of 18-23%. All ages are

affected uniformly. Men and women are affected with equivalent occurrence.



**Figure-1: It displays the chigger, life cycle and eschar formation**

The primary symptom is generally a minute raised mark at the site of the bite, and becomes blackish spot (eschar). It is frequently found near the groin, neck, armpits and in the external genital regions. Allied rash around the eschar and the lymph nodes near the pretentious area may become inflamed. Fever may start suddenly, accompanied constantly by chills, muscle pain, severe headache and cough. There may also be drowsiness, vomiting, redness of the eyes and shin pain. The presence of an eschar is important diagnostic evidence to the physician and on physical examination may evidence of liver enlargement, congestion of the lungs. Features of intractable cough, shortness of breath and drowsiness incase of sophisticated disease. Many laboratory tests can assist in diagnosing scrub typhus, including general and specific tests. [3]

**General tests:**

- Large number of white blood cells and a low level of platelets
- Abnormal hepatic and renal function tests
- Chest X-ray may reveal features of lung involvement
- Ultrasound of abdomen to confirm enlargement of liver or spleen

**Specific tests:**

**Case reports:**

We are presenting two cases of scrub typhus from coastal Andhra Pradesh and display the characteristics in table-1.

- ELISA for recognition of antibodies to the bacterium- used nowadays
- Blood culture
- PCR

**Complications:**

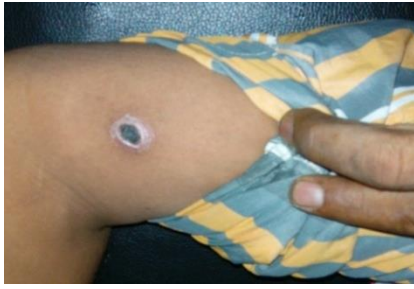- Pneumonitis
- Acute Lung Injury (ALI)
- Acute Respiratory Distress Syndrome (ARDS)
- Acute Kidney Injury (AKI)
- Myocarditis
- Septic shock
- Disseminated Intravascular Coagulation (DIC)
- In pregnancy - Preterm labour and Neonatal Respiratory Distress Syndrome [4]

Early initiation of treatment based on clinical suspicion. The suggested treatment is doxycycline 100 mg twice daily orally for 7 to 14 days based on the severity of the disease. Azithromycin 500 mg once daily is used in case of children and pregnant women. Azithromycin used in combination with rifampicin where resistance to doxycycline alone. Complications may necessitate supportive care in the ICU setting. Treatment guidelines as recommended in the Indian Medical Gazette include doxycycline as the treatment of choice in adults, and azithromycin in pregnancy. Alternatives to doxycycline comprise telithromycin, chloramphenicol, rifampicin, roxithromycin and levofloxacin. It is significant to note that rifampicin should not be used as a solitary agent. [5]

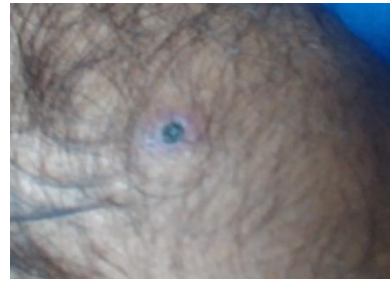

**Table-1: It display the characteristics of two cases of scrub typhus**

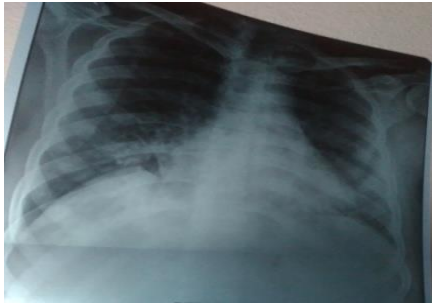
Characteristics	Case-1	Case-2
Age	30 years	40 years
Gender	Male	Male
Residence	Rural	Rural
Occupation	Carpenter	Farmer
PMH	No H/O HTN DM & BA	No H/O HTN DM & BA
HPI	Fever since 3 weeks Chills since 3 weeks Shortness of breath + Non-productive Cough Nausea B/L Pedal edema	Fever since 7 days Chills since 7 days Shortness of breath + Non-productive Cough but occasionally sputum production Spasmodic abdominal pain
Vital signs	Temperature- 102 <sup>0</sup> F Pulse Rate- 118 bpm Blood Pressure- 80/50 mm Hg Respiratory system: B/L crepts + P/A- Soft	Temperature- 101 <sup>0</sup> F Pulse Rate- 114 bpm Blood Pressure- 90/60 mm Hg Respiratory system: B/L crepts + P/A- Tenderness
Eschar	Left elbow region (Figure-1) and painful	Right upper abdomen (Figure-2) painful
Complications	Bilateral Pneumonitis Septic shock Splenomegaly	ARDS Bilateral Pneumonitis
CXR Inference	Lung involvement (Figure-3)	Lung involvement (Figure-4)
USG Notes	Splenomegaly	-
Blood Picture	Hemoglobin- 11.4 gm/dl (13-18 gm/dl) Platelet count- 20,000 (1,50,000- 4,50,000) ↓ ↓	Hemoglobin- 10.8 gm/dl (13-18 gm/dl) ↓ Platelet count- 25,000 (1,50,000- 4,50,000)
LFT	Total bilirubin- 1.4 mg/dl (0.2 to 1.2 mg/dl) ↑	Total bilirubin- 3.7 mg/dl (0.2 to 1.2 mg/dl) ↑ Direct bilirubin- 1.8 mg/dl (0.0 to 0.2 mg/dl) ↑ SGPT- 44 U (0-40 U) ↑
RFT	-	Serum creatinine-1.5 (0.6-1.2 mg/dl) ↑
ELISA	-	Positive
Treatment	Inj. Doxycycline 100 mg IV BD a drip in NS 100 ml for 6 days Inj. Azithromycin 500 mg IV BD a drip in NS 100 ml for 6 days Inj. Cefoperazone+ Sulbactam 1.5 gm IV BD for 3 days Ventilator support is provided	Cap. Doxycycline 100 mg P/O BD for 5 days Inj. Azithromycin 500 mg IV BD a drip in NS 100 ml for 5 days Inj. Piperacillin+Tazobactam 4.5 gm IV TID for 5 days Ventilator support is provided



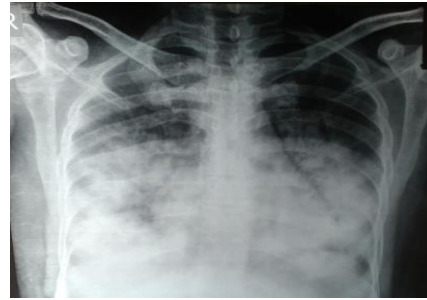
**Figure-1: It displays the eschar on left elbow region**



**Figure-2: It displays the eschar on right upper abdomen**



**Figure-3: It displays the lung involvement in case-1**



**Figure-4: It displays the lung involvement in case-2**

Based on the clinical picture of fever with eschar, a dramatic therapeutic response to doxycycline and Elisa test positivity, a final diagnosis of scrub typhus with bilateral pneumonitis and ARDS was made.

#### **DISCUSSION:**

These case reports show that scrub typhus infection is emerging threat in Nellore, coastal Andhra Pradesh. This febrile illness affects healthy active persons and if undiagnosed may establish to be life threatening. Numerous reports of scrub typhus from different parts of India have been available. It is frequently acquired during agricultural or occupational exposures because active rice fields are an imperative reservoir for transmission. It is transmitted to humans through the bite of an infected chigger. Wild rats serve as the likely reservoir for the chiggers and symbolize a risk factor for human infection. [6] Mainly cases of scrub typhus were diagnosed during the rainy months of June to November. These cases were diagnosed in the month of August supported by Mathai *et al.* [7] reported more cases in the cooler months in southern India. The bacteria reproduce at the inoculation site, and a papule forms that ulcerates and evolving into an eschar with generalized lymphadenopathy

(within a few days) and acute febrile illness (within 8-10 days of the chigger bite). The primary symptom is generally a minute raised mark at the site of the bite, and becomes blackish spot (eschar). Fever may start suddenly, accompanied constantly by chills, muscle pain, severe headache and cough. The presence of an eschar is important diagnostic evidence to the physician and on physical examination may evidence of liver enlargement. Features of intractable cough, shortness of breath are seen in these cases. Many laboratory tests can assist in diagnosing scrub typhus, including general and specific tests. Scrub typhus is under-diagnosed in India due to its distracted clinical presentation, low index of distrust among clinicians, limited awareness and short of diagnostic facilities. Low level of platelets, abnormal hepatic and renal function tests, Splenomegaly, lung involvement, abnormal hemoglobin levels and positive ELISA test confirm the diagnosis in these cases. Serious complications include Pneumonitis, Acute

Respiratory Distress Syndrome and Septic shock are implicated in these cases. Early diagnosis is significant and suitable antimicrobial therapy may help avert complications.<sup>[8]</sup> In these cases, the patients presented extremely late – 7 days after his illness started. Primarily, we suspected bilateral pneumonia with sepsis. In the initial examination, we find the eschar. So, we started Azithromycin and doxycycline.

#### **CONCLUSION:**

Early treatment shows better outcomes and faster resolution than delayed treatment. In this perspective, we expect this report will make physicians alert of this entity which is possibly more extensive than considered.

**Abbreviations:** ARDS- Acute respiratory distress syndrome, BA- Bronchial asthma, CXR- Chest x-ray, DM- Diabetes mellitus, ELISA- Enzyme linked immune sorbent assay, HPI- History of present illness, HTN- Hypertension, LFT'S- Liver function tests, PMH- Past medical history, RFT'S- Renal function tests, SGPT- Serum glutamate pyruvate transaminase, USG- Ultrasonography.

#### **REFERENCES:**

1. Ittyachen AM. Emerging infections in Kerala: A case of scrub typhus. *Natl Med J India.* 2009; 22:333–4.
2. Chrispal A, Boorugu H, Gopinath KG, Prakash JA, Chandy S, Abraham OC, et al. Scrub typhus: An unrecognized threat in South India - clinical profile and predictors of mortality. *Trop Doct.* 2010; 40:129–33.
3. Razak A, Sathyanarayanan V, Prabhu M, Sangar M, Balasubramanian R. Scrub typhus in Southern India: Are we doing enough? *Trop Doct.* 2010; 40:149–51.
4. Vivekanandan M, Mani A, Priya YS, Singh AP, Jayakumar S, Purty S. Outbreak of scrub typhus in

- Pondicherry. *J Assoc Physicians India.* 2010; 58:24–8.
5. Kim DE, Lee SH, Park KI, Chang KH, Roh JK. Scrub typhus encephalomyelitis with prominent neurological signs. *Arch Neurol.* 2000; 57:1770–2.
6. Mathai E, Rolain JM, Verghese GM, Abraham OC, Mathai D, Mathai M, et al. Outbreak of scrub typhus in southern India during the cooler months. *Ann N Y Acad Sci.* 2003; 990:359–64.
7. Yang SH, Wang LS, Liang CC, Ho YH, Chang ET, Cheng CH. Scrub typhus complicated by intracranial hemorrhage - A Case report. *Tzu Chi Med J.* 2005; 17:111–4.
8. Mahajan SK, Rolain JM, Kashyap R, Bakshi D, Sharma V, Prasher BS, et al. Scrub typhus in Himalayas. *Emerg Infect Dis.* 2006; 12:1590–2.

\*\*\*\*\*